

# Endocarditis update for 2016

Nathaniel J Dittoe MD FACC

# Presentation Goals

Discuss epidemiology of endocarditis

Outline contributing factors and define “at risk population”

Give an overview of diagnostic criteria and testing used to confirm suspected diagnosis

Discuss general treatment principles

Summary and take home points



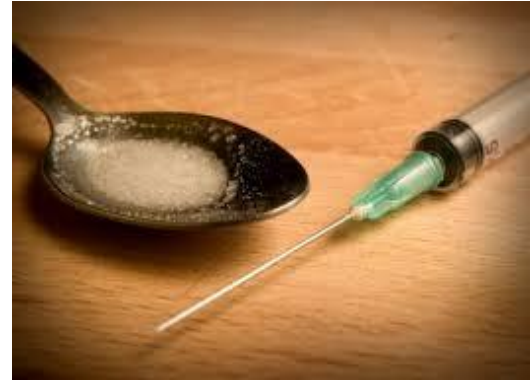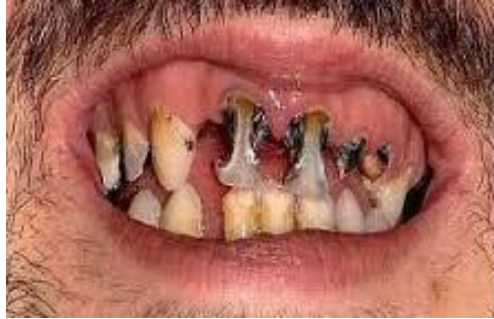# Epidemiology

- Incidence has increased from 11 to 15 per 100,000 population in US
- Difficult to get exact numbers due to varying clinical definitions and risk factor changes
- Reasons for increase are unclear, but there is some concern about the change in antibiotic prophylaxis guidelines in 2007




# Patient Risk Factors

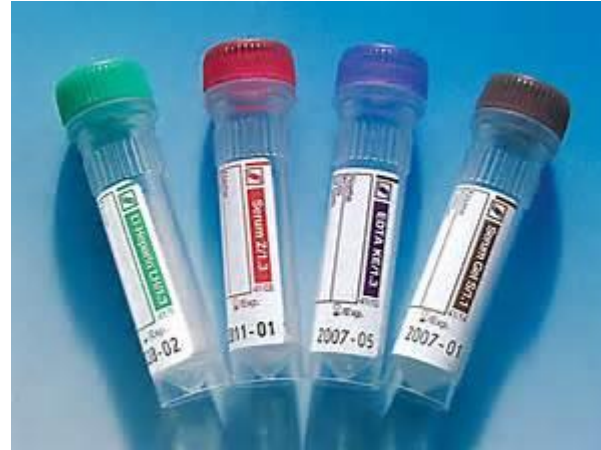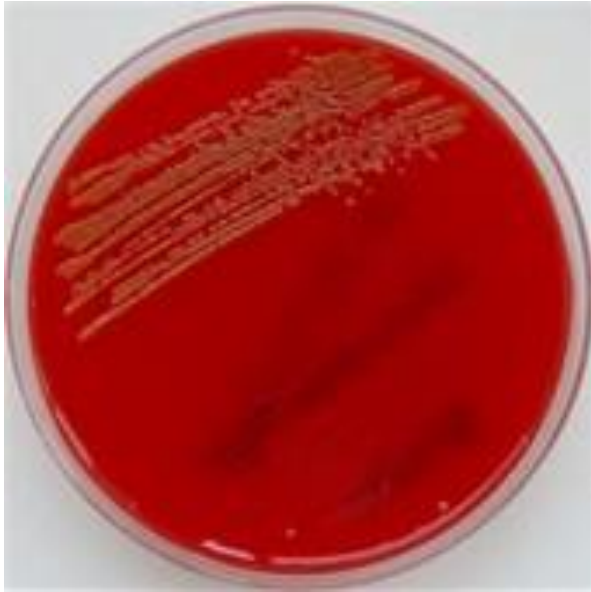- Age >60
- Male Sex
- IV drug users
- Poor dentition or dental infection
- Structural heart disease(75%)
  - Endocarditis patients without were more likely to be immunosuppressed



# Comorbidities

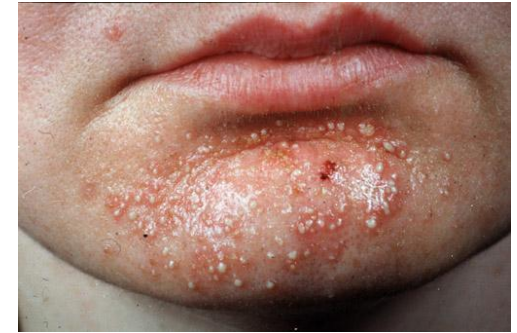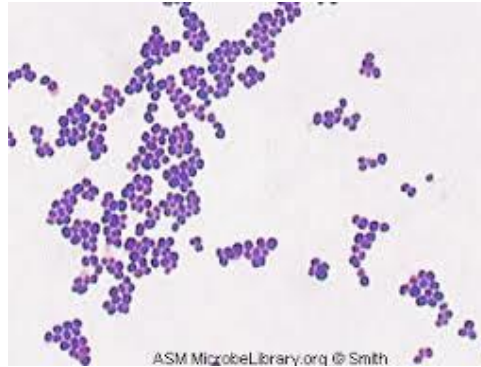
- Valvular heart disease (rheumatic heart disease, mitral valve prolapse with regurgitation)
  - Congenital heart disease( ie, bicuspid aortic valve, VSD, patent ductus arteriosus, tetralogy of fallot)
  - Prosthetic heart valves (or other intracardiac devices)
  - Chronic Hemodialysis
  - HIV infection
- 

# Microbiology



# Microbiology

- *Staphylococcus. Aureus*- 31%
- Viridans group streptococci- 17%
- Enterococcus- 11%
- Coagulase negative staphylococci- 11%
- *Streptococcus bovis*- 7%
- Other streptococci- 5%
- Fungi- 2%
- HACEK -2%(*Haemophilus aphrophilus* *Actinobacillus actinomycetemcomitans* (subsequently called *Aggregatibacter actinomycetemcomitans*); *Cardiobacterium hominis*; *Eikenella corrodens*; and *Kingella kingae*)
- Non HACEK -2%
- Other- 11%



# Biofilm Definition

- A surface attached microcolony of microbes encased in a self-produced of extracellular polymeric substances (EPS)
- Microbial cells are only 15% of volume
- EPS acts as protective slime layer and contains variable substances depending on organism.
  - Can contain polysaccharides, extracellular DNA and proteins
  - 95% water and forms a gelatinous matrix that keeps the biofilm and organisms together

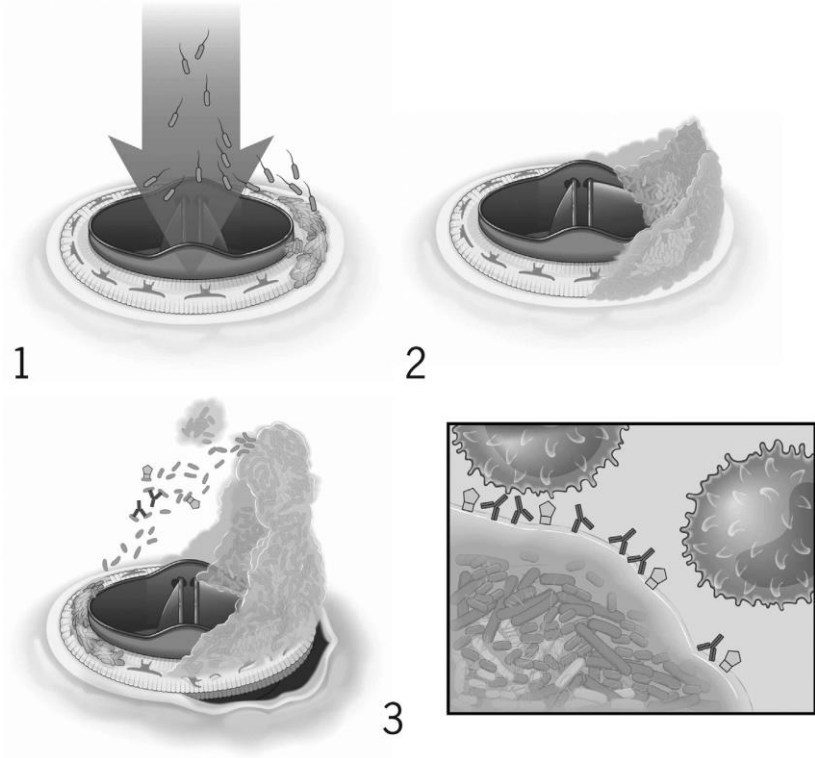




- Within the biofilm, loosely attached **planktonic** cells are located near surface and can be dispersed to colonize surrounding structures
- Deeper within are “**sustaining**” cells, which help maintain the biofilm, and creates a chemical environment which upregulates organism stress genes
  - Protected from host immune cells and antibodies
  - Antibiotic resistance

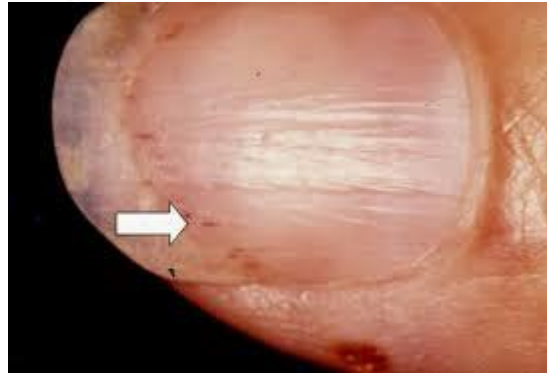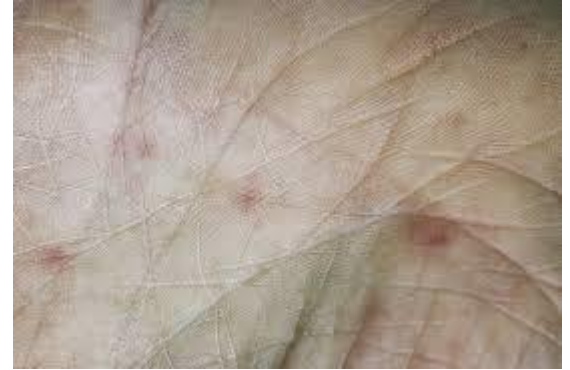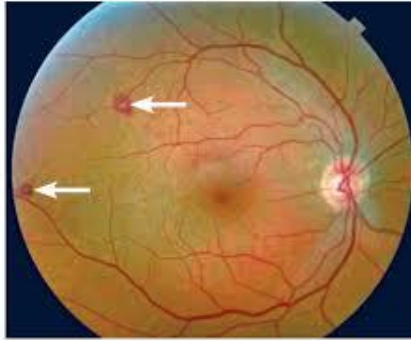


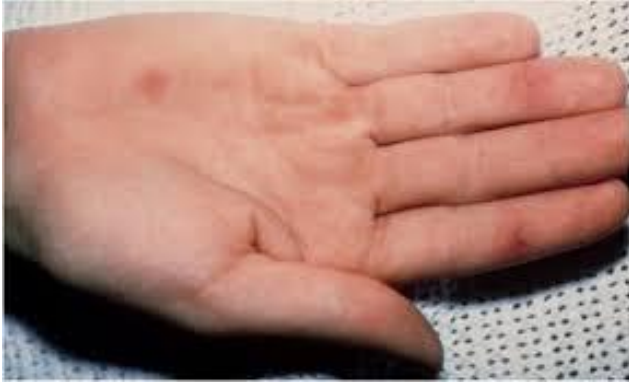# Biofilm cycle



1. Attachment
2. Biofilm growth and maturation
3. Embolic dispersion and protection

# Clinical Manifestations




# Clinical Manifestations

- Variable presentation
- Can be rapidly progressive fulminant infection
- Can also be subclinical and asymptomatic



# Clinical Manifestations-Symptoms

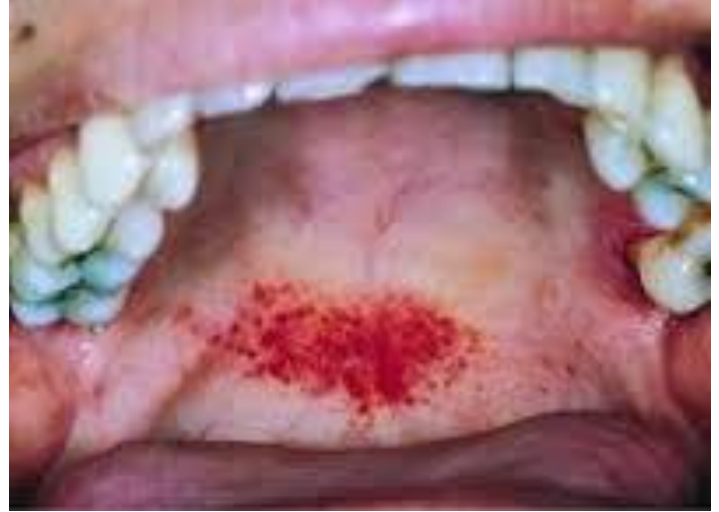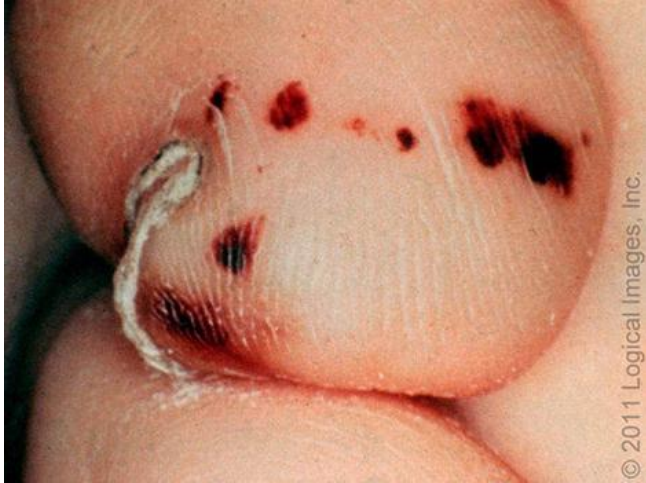- Fever- 90%
    - Often associated with chills, anorexia, weight loss, malaise, night sweats
    - Abdominal pain, dyspnea, cough, and pleuritic pain
    - Patients with IE associated with dental infection may report tooth pain or related symptoms
- 

# Clinical Manifestations-Signs

- Cardiac murmurs can be heard in up to 85% of patients
- Splenomegaly
- Cutaneous manifestations

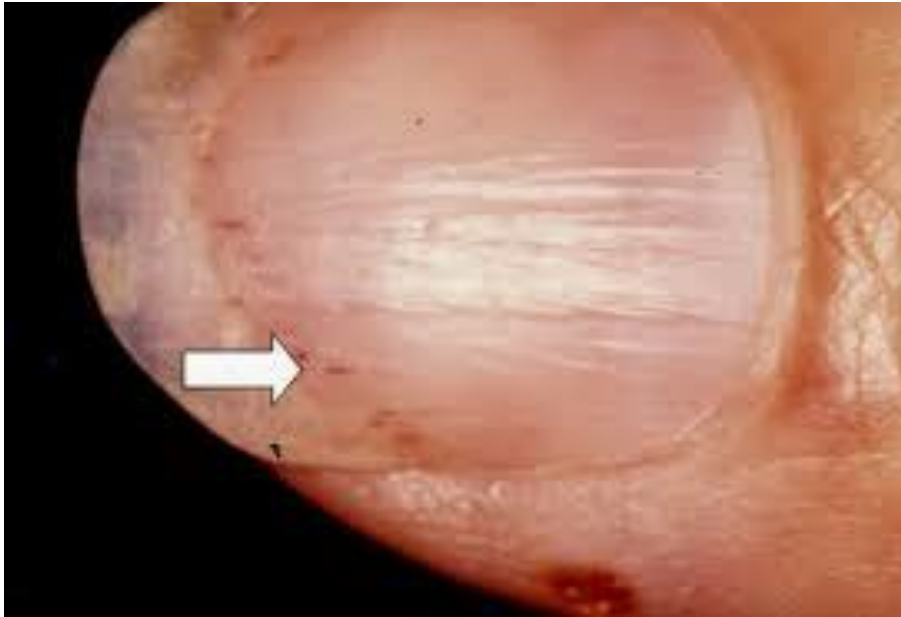


# Clinical Manifestations-Signs



Petechiae may be present on skin or mucous membranes (20-40%), another reason to look inside the mouth.

# Clinical Manifestations-Signs



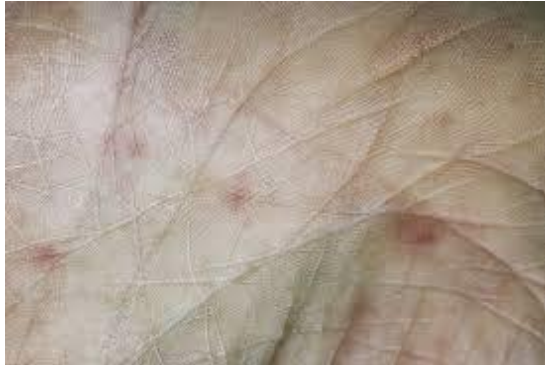## **Splinter Hemorrhages**

Caused by microembolic damage to nail bed capillaries



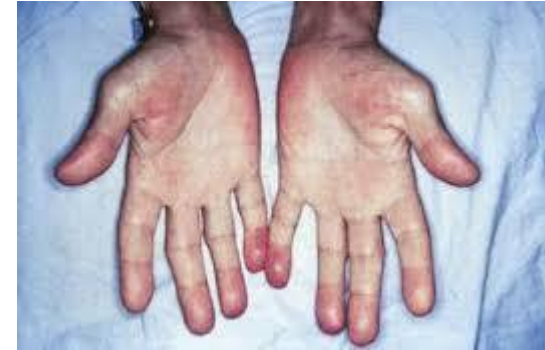# Clinical Manifestations-Signs

## Janeway Lesions

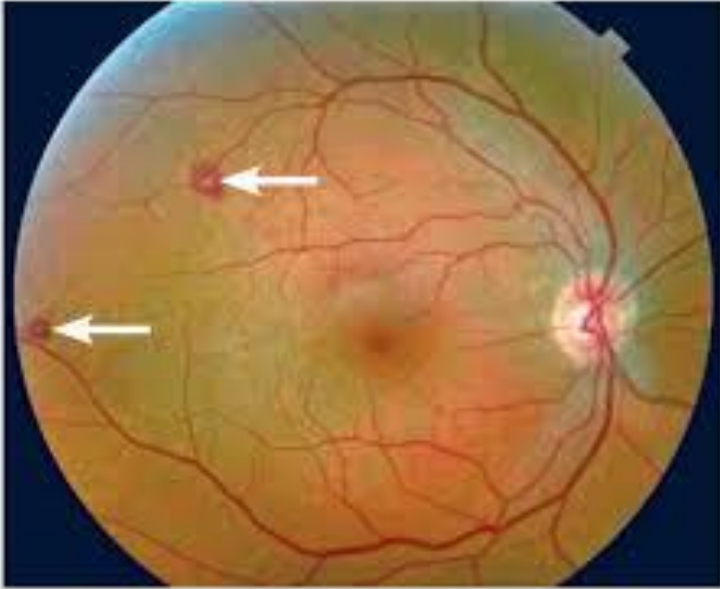


Variable	Janeway lesion	Osler node
Location	Soles, palms, thenar and hypothenar eminences, plantar surfaces of the toe	Finger and toe tips, thenar and hypothenar eminences
Size and shape	Macules of variable size and irregular shape	Nodules of 1 mm to > 1 cm
Tender	No	Yes
Course	Days to weeks	Hours to days
Type of endocarditis	Acute	Subacute
Culture	Positive, usually	Negative, usually
Histology	Septic microemboli	Vasculitis

## Osler Nodes



# Clinical Manifestations-Signs

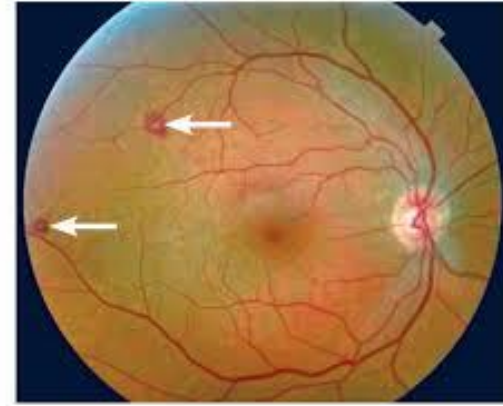
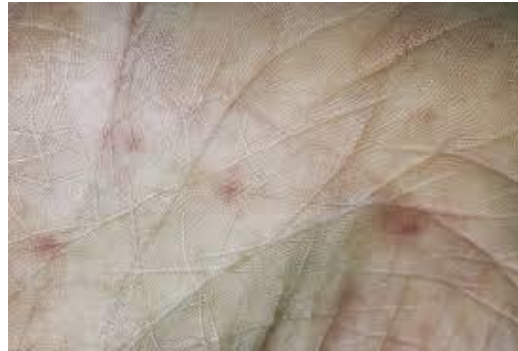
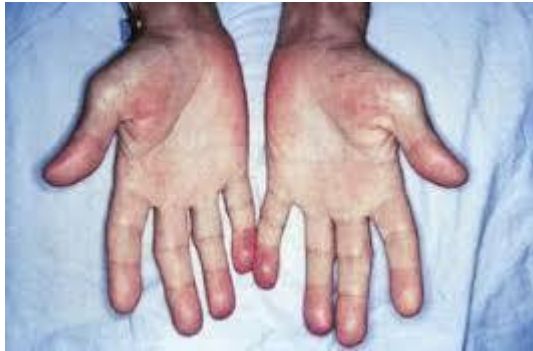
## **Roth Spots**


Exudative, edematous hemorrhagic lesions of the retina with pale centers

# Clinical Manifestations-Signs

Osler nodes, Janeway lesions and Roth spots are not particularly common, but if seen **Highly Suggestive** of endocarditis



# Systemic Presentations


- Cardiac complications (up to 50 percent of patients) – Valvular insufficiency, heart failure, and others
  - Neurologic complications (up to 40 percent of patients) – Embolic stroke, intracerebral hemorrhage, brain abscess
  - Septic emboli (up to 25 percent of patients) – Infarction of kidneys, spleen, and other organs. In right-sided endocarditis (common among intravenous drug users), septic pulmonary emboli may be seen
  - Metastatic infection (such as vertebral osteomyelitis, septic arthritis, psoas abscess)
  - Systemic immune reaction (eg, glomerulonephritis)
- 

# Laboratory and Imaging Findings

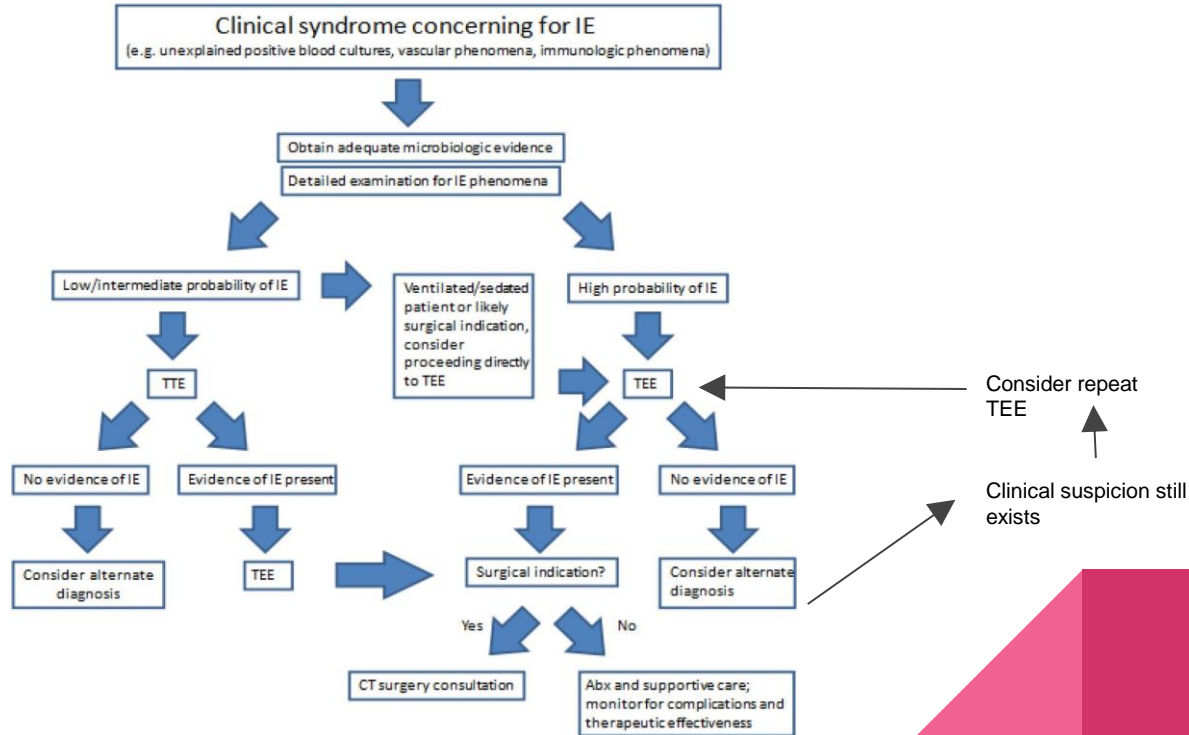
- Can be non-specific
- Elevated WBC, ESR, CRP
- Normocytic, normochromic anemia
- Red cell casts on UA, may indicate glomerulonephritis (minor Duke Criteria)
- Blood Cultures results crucial



# Imaging/Testing

- ECG
    - New 1st degree AV block, bundle branch block or complete AV block. (suspect aortic valve involvement)
  - Transthoracic echocardiography
    - Reasonable as first choice in many cases, but negative study does not rule out endocarditis
  - Transesophageal echocardiography
    - Better resolution, and allows visualization of some structures that are not well seen on transthoracic echo
    - Sensitivity of in the range 92-94% for detecting endocarditis(not 100%)
    - Allows better visualization and evaluation of the extent of known endocarditis
- 

# Echocardiogram Algorithm in suspected IE



## Modified Duke criteria for diagnosis of infective endocarditis - Table A

<b>Definite IE is established in the presence of any of the following:</b>
<b>Pathologic criteria</b>
Pathologic lesions: vegetation or intracardiac abscess demonstrating active endocarditis on histology <b>OR</b>
Microorganism: demonstrated by culture or histology of a vegetation or intracardiac abscess
<b>Clinical criteria</b>
Using specific definitions listed in <b>Table B:</b>
2 major clinical criteria <b>OR</b>
1 major and 3 minor clinical criteria <b>OR</b>
5 minor clinical criteria
<b>Possible IE*</b>
Presence of 1 major and 1 minor clinical criteria <b>OR</b> presence of 3 minor clinical criteria
<b>Rejected IE</b>
A firm alternate diagnosis is made <b>OR</b>
Resolution of clinical manifestations occurs after $\leq 4$ days of antibiotic therapy <b>OR</b>
No pathologic evidence of infective endocarditis is found at surgery or autopsy after antibiotic therapy for four days or less
Clinical criteria for possible or definite IE not met

IE: infective endocarditis.

\* The category of possible IE represents a modification from the previous published Duke criteria.

Reproduced with permission from: Li JS, Sexton DJ, Mick N, et al. Clin Infect Dis 2000; 30:633. Copyright © 2000 University of Chicago Press.

UpToDate®

## Modified Duke criteria for diagnosis of infective endocarditis - Table B

<b>Major criteria</b>
<b>Positive blood cultures for IE (one of the following):</b>
<b>Typical microorganisms consistent with IE from two separate blood cultures:</b>
<i>Staphylococcus aureus</i>
Viridans streptococci
<i>Streptococcus gallolyticus</i> (formerly <i>S. bovis</i> ), including nutritional variant strains ( <i>Granulicatella</i> spp and <i>Abiotrophia defectiva</i> )
HACEK group: <i>Haemophilus</i> spp, <i>Aggregatibacter</i> (formerly <i>Actinobacillus actinomycete comitans</i> ), <i>Cardiobacterium hominis</i> , <i>Eikenella</i> spp, and <i>Kingella kingae</i>
Community-acquired enterococci, in the absence of a primary focus; <b>OR</b>
<b>Persistently positive blood culture:</b>
For organisms that are typical causes of IE: At least two positive blood cultures from blood samples drawn $>12$ hours apart
For organisms that are more commonly skin contaminants: Three or a majority of $\geq 4$ separate blood cultures (with first and last drawn at least one hour apart)
<b>Single positive blood culture for <i>Coxiella burnetii</i> or phase I IgG antibody titer <math>&gt;1:800</math>**</b>
<b>Evidence of endocardial involvement (one of the following):</b>
<b>Echocardiogram positive for IE:</b>
Vegetation (oscillating intracardiac mass on a valve or on supporting structures, in the path of regurgitant jets, or on implanted material, in the absence of an alternative anatomic explanation) <b>OR</b>
Abscess <b>OR</b>
New partial dehiscence of prosthetic valve
<b>New valvular regurgitation</b>
Increase in or change in preexisting murmur not sufficient
<b>Minor criteria</b>
Predisposition: Intravenous drug use or presence of a predisposing heart condition (prosthetic heart valve or a valve lesion associated with significant regurgitation or turbulence of blood flow)
Fever: Temperature $\geq 38.0^{\circ}\text{C}$ ( $100.4^{\circ}\text{F}$ )
Vascular phenomena: Major arterial emboli, septic pulmonary infarcts, mycotic aneurysm, intracranial hemorrhage, conjunctival hemorrhages, or Janeway lesions
Immunologic phenomena: Glomerulonephritis, Osler nodes, Roth spots, or rheumatoid factor
Microbiologic evidence: Positive blood cultures that do not meet major criteria <b>OR</b> serologic evidence of active infection with organism consistent with IE
(Echocardiographic minor criteria eliminated)**

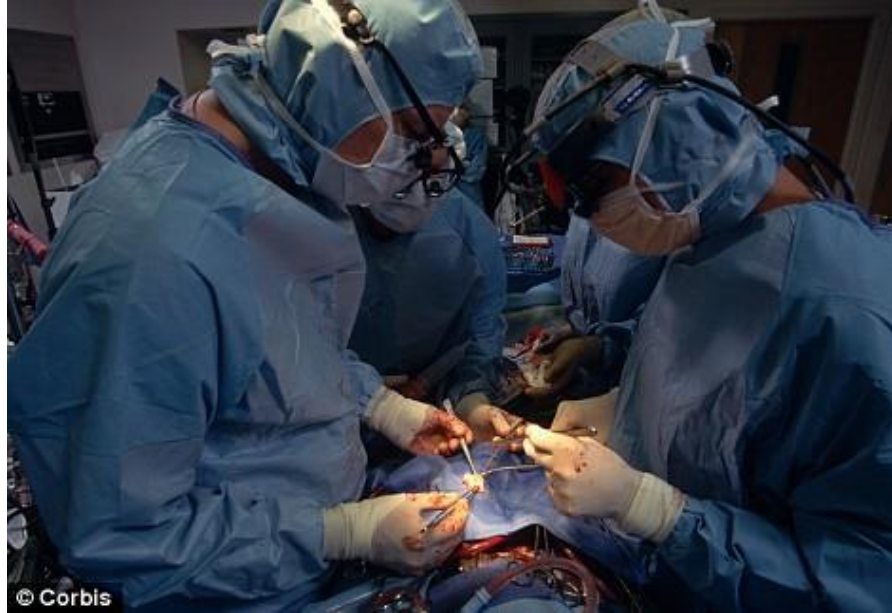IE: infective endocarditis; TEE: transesophageal echocardiography; TTE: transthoracic echocardiography.  
\*\* Modifications from the previous published Duke criteria are noted by the astenisk.

Reproduced with permission from: Li JS, Sexton DJ, Mick N, et al. Clin Infect Dis 2000; 30:633. Copyright © 2000 University of Chicago Press.

UpToDate®

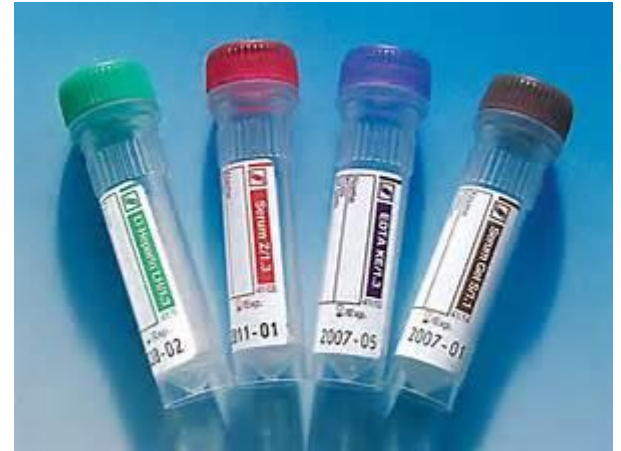

# Treatment



# Endocarditis Medical Treatment

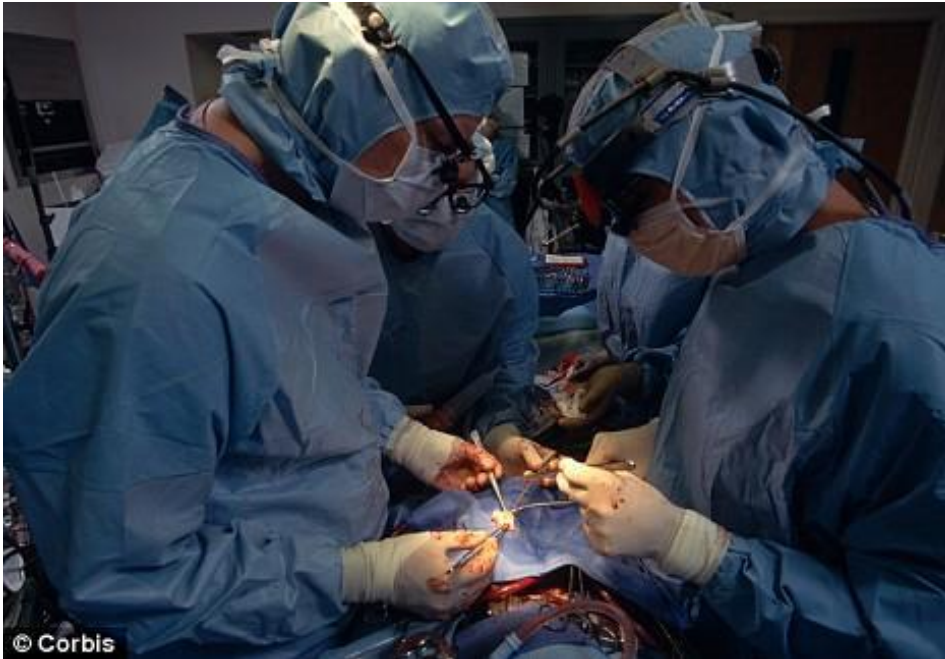- Critical to draw blood cultures first!
  - Will be positive in 90% cases and can tailor RX
- If patient is very ill and diagnosis of IE is likely
  - Consider empiric treatment
  - Cover Staphylococcus, streptococcus and enterococcus
  - Vancomycin is a good option
- Use cultures to guide further therapy options
  - Repeat every 24-48 hour to assess response
  - Close clinical assessment
    - Look for embolic stigmata
    - Auscultation for new or worsening murmurs
    - Continuous telemetry



# Endocarditis Medical Treatment

- Can follow response to treatment with markers of inflammation (CBC, ESR,CRP)
- Need thorough dental evaluation
- Referral for treatment for IV drug users
- Duration of antibiotic treatment is variable depending on organism, site of infection and severity
  - Range from 2 weeks in uncomplicated right sided endocarditis with susceptible organisms, to 6 weeks or longer.

# Endocarditis Surgical Treatment



# Applying Classification of Recommendations and Level of Evidence

## “SIZE of TREATMENT EFFECT”

“Estimate of Certainty (Precision) of Treatment Effect”

	<b>Class I</b>  <i>Benefit &gt;&gt;&gt; Risk</i> <i>No additional studies needed</i>  <b>Procedure/Treatment SHOULD be performed/administered</b>	<b>Class IIa</b>  <i>Benefit &gt;&gt; Risk</i> <i>Additional studies with focused objectives needed</i>  <b>IT IS REASONABLE to perform procedure/administer treatment</b>	<b>Class IIb</b>  <i>Benefit ≥ Risk</i> <i>Additional studies with broad objectives needed; Additional registry data would be helpful</i>  <b>IT IS NOT UNREASONABLE to perform procedure/administer treatment</b>	<b>Class III</b>  <i>Risk ≥ Benefit</i> <i>No additional studies needed</i>  <b>Procedure/Treatment should NOT be performed/administered SINCE IT IS NOT HELPFUL AND MAY BE HARMFUL.</b>
<b>Level A</b>  <i>Multiple (3-5) population risk strata evaluated</i>  <i>General consistency of direction and magnitude of effect</i>	<ul style="list-style-type: none"> <li>• Recommendation that procedure or treatment is useful/effective</li> <li>• Sufficient evidence from multiple randomized trials or meta-analyses</li> </ul>	<ul style="list-style-type: none"> <li>• Recommendation in favor of treatment or procedure being useful/effective</li> <li>• Some conflicting evidence from multiple randomized trials or meta-analyses</li> </ul>	<ul style="list-style-type: none"> <li>• Recommendation’s usefulness/efficacy less well established</li> <li>• Greater conflicting evidence from multiple randomized trials or meta-analyses</li> </ul>	<ul style="list-style-type: none"> <li>• Recommendation that procedure or treatment not useful/effective and may be harmful</li> <li>• Sufficient evidence from multiple randomized trials or meta-analyses</li> </ul>
<b>Level B</b>  <i>Limited (2-3) population risk strata evaluated</i>	<ul style="list-style-type: none"> <li>• Recommendation that procedure or treatment is useful/effective</li> <li>• Limited evidence from single randomized trial or non-randomized studies</li> </ul>	<ul style="list-style-type: none"> <li>• Recommendation in favor of treatment or procedure being useful/ effective</li> <li>• Some conflicting evidence from single randomized trial or non-randomized studies</li> </ul>	<ul style="list-style-type: none"> <li>• Recommendation’s usefulness/efficacy less well established</li> <li>• Greater conflicting evidence from single randomized trial or non-randomized studies</li> </ul>	<ul style="list-style-type: none"> <li>• Recommendation that procedure or treatment not useful/effective and may be harmful</li> <li>• Limited evidence from single randomized trial or non-randomized studies</li> </ul>
<b>Level C</b>  <i>Very limited (1-2) population risk strata evaluated</i>	<ul style="list-style-type: none"> <li>• Recommendation that procedure or treatment is useful/effective</li> <li>• Only expert opinion, case studies, or standard-of-care</li> </ul>	<ul style="list-style-type: none"> <li>• Recommendation in favor of treatment or procedure being useful/ effective</li> <li>• Only diverging expert opinion, case studies, or standard-of-care</li> </ul>	<ul style="list-style-type: none"> <li>• Recommendation’s usefulness/efficacy less well established</li> <li>• Only diverging expert opinion, case studies, or standard-of-care</li> </ul>	<ul style="list-style-type: none"> <li>• Recommendation that procedure or treatment not useful/effective and may be harmful</li> <li>• Only expert opinion, case studies, or standard-of-care</li> </ul>

# Endocarditis Surgical Treatment

- Indications for early surgery in native left sided endocarditis-Class I (LOE)
  - Severe valve dysfunction with signs of heart failure(B)
  - Paravalvular extension of infection, aortic abscess, heart block(B)
  - Difficult to treat pathogen(multidrug resistance, fungal)(B)
  - Persistent infection
    - Bacteremia or fever lasting 5-7 days post appropriate antimicrobial drug initiation(B)



# Endocarditis Surgical Treatment

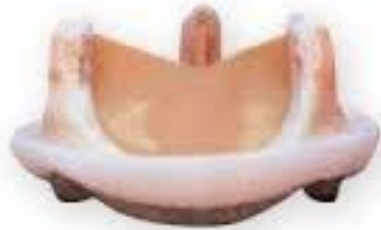- Indications for early surgery in native left sided endocarditis-Class II(LOE)
  - Recurrent embolisms, or enlarging vegetations despite appropriate antimicrobial therapy(B)
  - >10mm mobile vegetations with severe valve regurgitation(B)
  - >10mm mobile vegetations involving anterior mitral valve leaflet and other relative indications for surgery(C)



# Endocarditis Surgical Treatment

Left sided prosthetic valve early surgery indications are almost identical

Indication for relapsing prosthetic valve infection (II)(B)



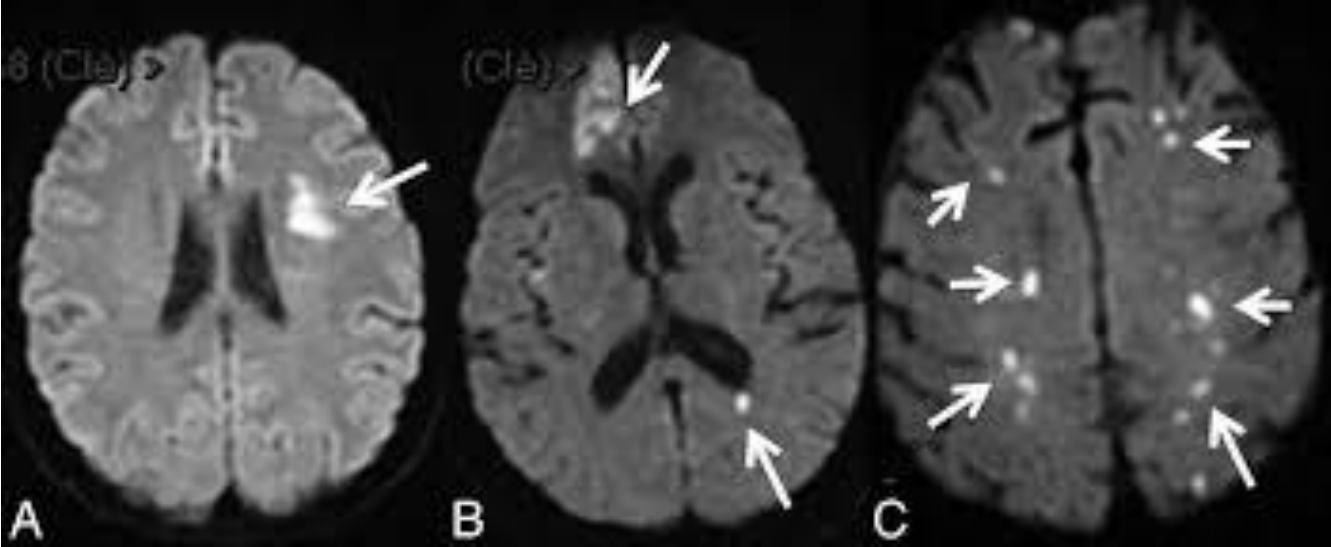


# Endocarditis Surgical Treatment

- Guidelines for surgery right sided endocarditis are different
  - Many can be treated medically
  - Frequently associated with IV drug users (needs to be considered before surgery)
  - Indications for surgery include
    - Right sided heart failure due to severe tricuspid regurgitation
    - Poor response to therapy
    - Multidrug resistant organisms
    - Recurrent septic pulmonary emboli despite therapy
  - If surgery is indicated valve repair is favored over replacement
  - If patient is active IV drug user, avoiding surgery is reasonable if possible



# Endocarditis Surgical Treatment in Stroke




# Endocarditis Surgical Treatment

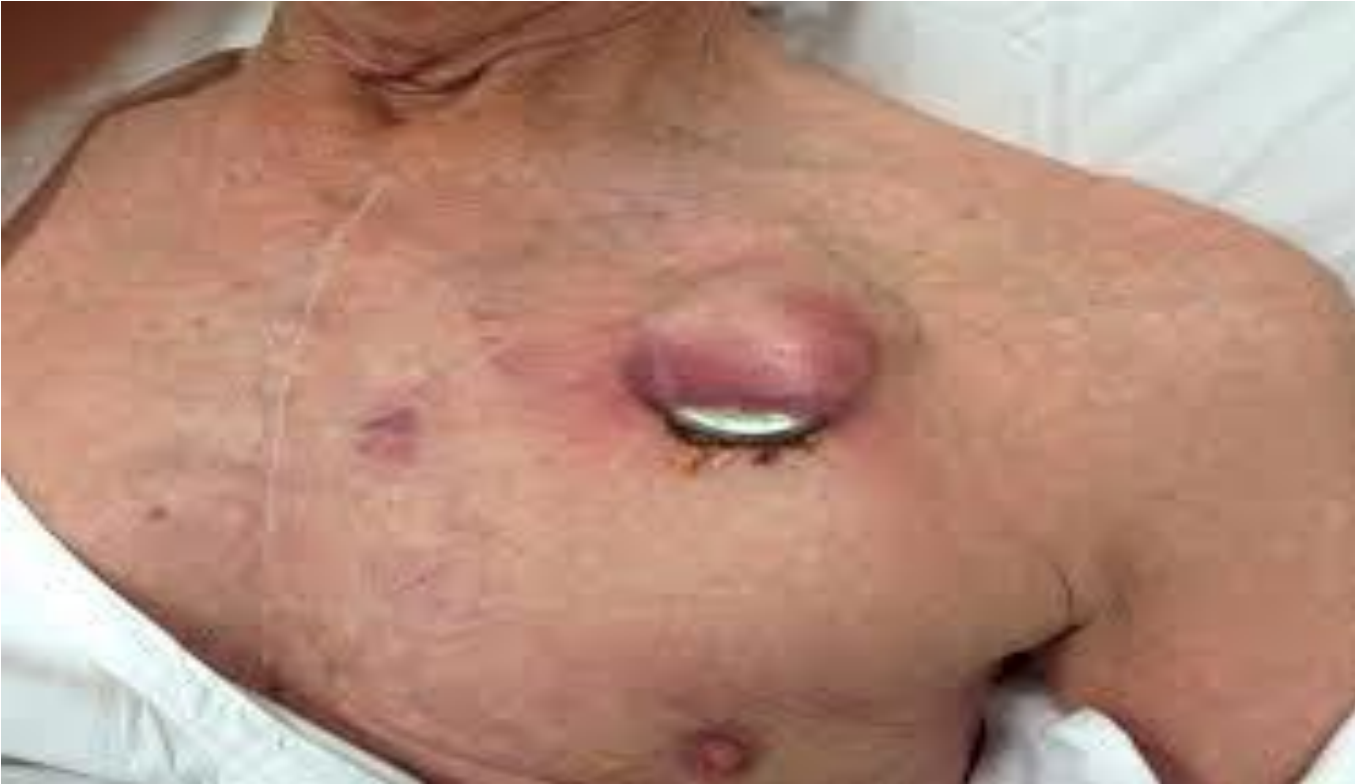- **Valve surgery may be considered in IE patients with stroke or subclinical cerebral emboli and residual vegetation without delay if intracranial hemorrhage has been excluded by imaging studies and neurological damage is not severe (ie, coma) (*Class IIb; Level of Evidence B*).**
- **In patients with major ischemic stroke or intracranial hemorrhage, it is reasonable to delay valve surgery for at least 4 weeks (*Class IIa; Level of Evidence B*).**
- ***Evidence B*.**



# Embolic Complications

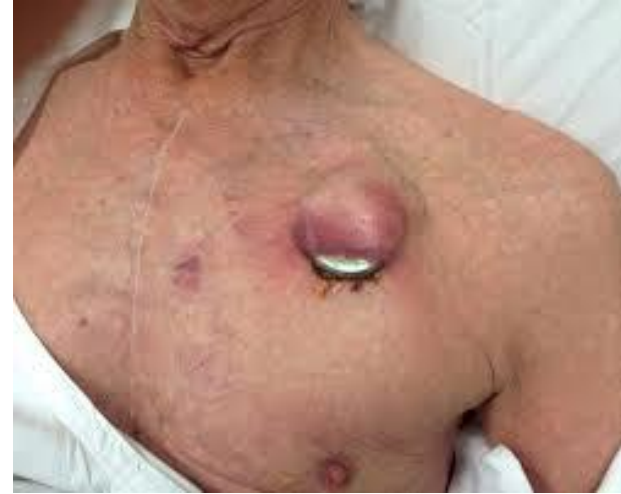- Stroke is most common (up to 65%)
  - Can happen before diagnosis, during treatment or after completion of therapy
  - Antimicrobial therapy treatment reduces risk
  - Size of embolism found to increase risk in some but not all studies
    - Typically greater than 10mm
  - Enlarging vegetation while on therapy predicts increased risk of embolic events
- 

# Device Infections

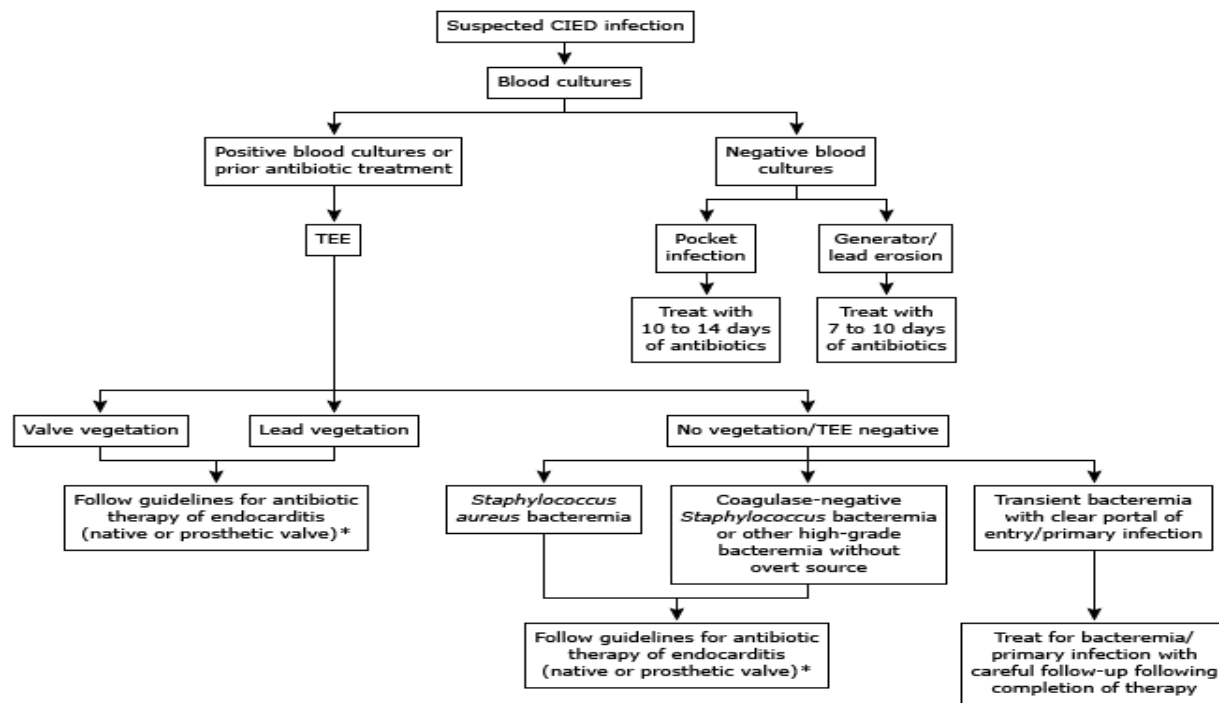


# Device infections

- Can be summed up in one sentence
- “If there is a device infection, it needs to come out.”
  - Entire system (generator and leads)
  - Always exceptions
  - Very ill patient may not tolerate lead extractions well
  - Pacemaker dependant patients can be challenging
    - Need for temporary pacing solution
    - Reimplantation only after infection has been treated
    - Different site



## Approach to antibiotic management of adults with cardiac electronic device infection



Duration of antibiotics should be counted from the day of device explantation.

CIED: cardiac implantable electronic device; TEE: transesophageal echocardiography.


\* Extracardiac infection may require tailored therapy depending on individual clinical circumstances.

Original figure modified for this publication. Sohail MR, Uslan DZ, Khan AH, et al. Management and outcome of permanent pacemaker and implantable cardioverter-defibrillator infections. *J Am Coll Cardiol* 2007; 49:1851.

Illustration used with the permission of Elsevier Inc. All rights reserved.

# Endocarditis prophylaxis

## **Patients at high risk for endocarditis:**

- Prosthetic heart valves, including bioprosthetic and homograft valves
  - A prior history of IE
  - Unrepaired cyanotic congenital heart disease, including palliative shunts and conduits
  - Completely repaired congenital heart defects with prosthetic material or device during the first six months after the procedure (whether placed by surgery or by catheter intervention)
  - Repaired congenital heart disease with residual defects at the site or adjacent to the site of the prosthetic patch or prosthetic device
  - Valve regurgitation due to a structurally abnormal valve in a transplanted heart
- 

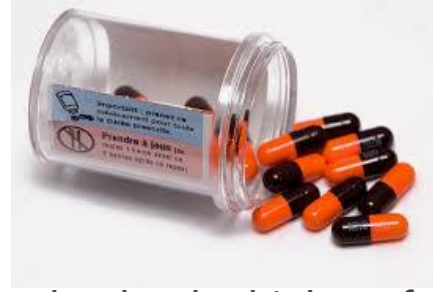

# Endocarditis Prophylaxis

Patients with pacemakers or ICDs **not** recommended to take antibiotic prophylaxis



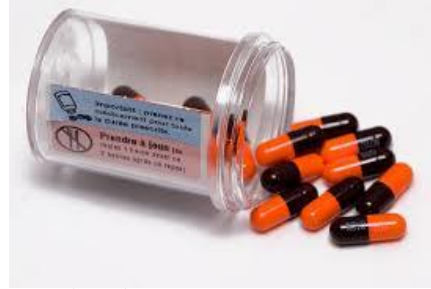# Endocarditis Prophylaxis



Dental work – The risk of IE is generally considered to be the highest for dental procedures that involve manipulation of gingival tissue or the periapical region of the teeth or perforation of the oral mucosa, such as tooth extractions or drainage of a dental abscess; this includes routine dental cleaning

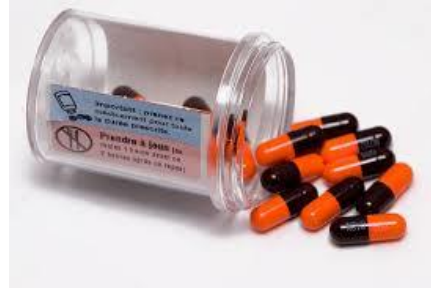There is no direct evidence that bacteremia associated with respiratory tract procedures causes IE. Antimicrobial prophylaxis is suggested only for procedures involving incision or biopsy of the respiratory tract mucosa; examples include tonsillectomy, adenoidectomy, or bronchoscopy with biopsy

# Endocarditis Prophylaxis



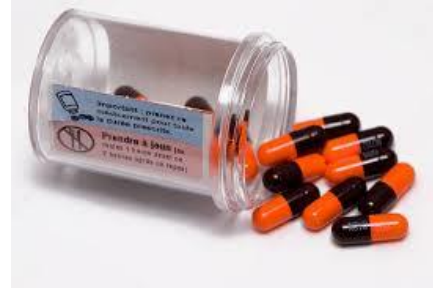**No routine prophylaxis for gastrointestinal (GI) or genitourinary (GU) procedures, even for patients with high-risk cardiac conditions. The risk of bacteremia for invasive GU procedures such as dilation of strictures, insertions of catheters, and prostatectomy is relatively low. The risk of bacteremia for invasive GI procedures such as lower bowel endoscopy with biopsy or endoscopic retrograde cholangiopancreatography is also low**

# Endocarditis Prophylaxis




Synthetic vascular grafts — Both the AHA and ASGE guidelines concluded that antibiotics are not necessary in patients with vascular grafts that have been in place for at least six months. However, the AHA (but not the ASGE) recommends antibiotic prophylaxis for procedures within the first six months of graft placement to permit time for endothelialization of the graft.

# Endocarditis Prophylaxis

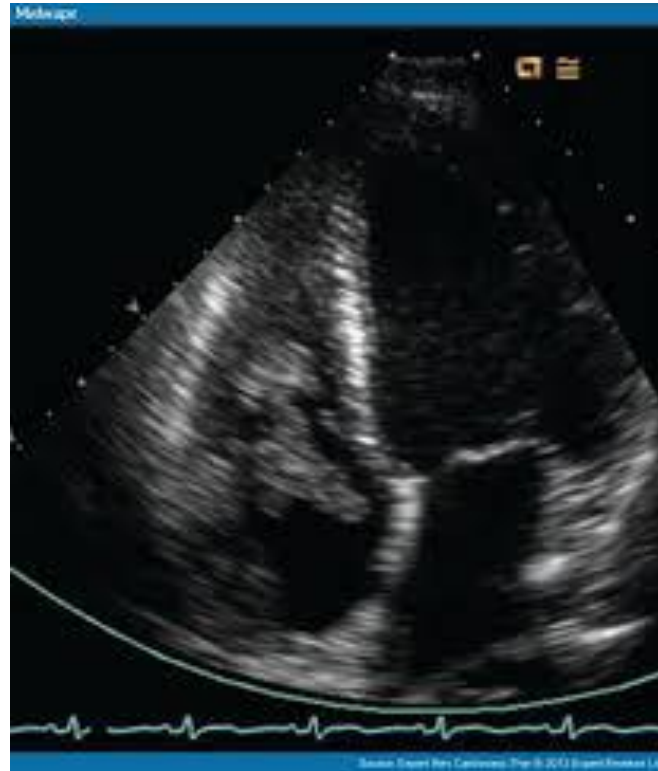

Patients undergoing a surgical procedure for management of infected skin, skin structure, or musculoskeletal tissue should receive antibiotic therapy with activity against staphylococci and beta-hemolytic streptococci.

# Trends in Endocarditis


- There has been an increase in the incidence of endocarditis since change in antibiotic prophylaxis guidelines
  - Some concern for a causal relationship
  - Other factors may be contributing
    - Increase of patient risk factors
    - More procedures being performed that puts patient at risk
    - Lower threshold for diagnosis (better imaging techniques?)
  - In the United Kingdom they are revisiting their prophylaxis guidelines
  - In US no change in ACC/AHA endocarditis
  - No definitive data can prove that changes in guidelines are warranted
- 

# Clinical Case



# Case


A 50 year old male presents to the ED with 1 week history of fevers, chills, night sweats and malaise. He has not seen a physician in over 20 years. He was told he had a “murmur” at his last exam but had no follow up. He states that he had noticed the symptoms becoming more severe over the last 48 hours. He denies any chest pains, but does state he feels short of breath. He denies any previous cardiac history and states he takes no medications. He denies any allergies or recent travel history. The only thing he states he has noticed is a non-healing wound on his left lower extremity 1<sup>st</sup> digit. He states it has been draining “yellow stuff” and painful over the last 2 weeks.





# Case

## On Exam

- Vitals: Temp 101.7, P95, R20, BP 100/40 BMI 40
  - Gen: Ax0 x 3, appears anxious and diaphoretic
  - HEENT: Dentition appears intact, mucosal petechiae noted on soft palate
  - Heart: Regular rate and rhythm Grade IV/VI harsh systolic murmur appreciated in right 2<sup>nd</sup> interspace which radiates to carotids. Grade II/VI diastolic murmur appreciated in right second interspace appreciated when patient leans forward and exhales.
  - Lungs: Scattered wheezes with rales at the bases
  - Abdomen: Soft, non tender, non distended, spleen is palpable 2 cm below the costal margin, bowel sounds are normal
  - Skin: Cool to the touch
  - Neurological: CN-II-XII grossly intact, no focal weakness
  - Ext: No cyanosis, clubbing, warm erythematous left 1<sup>st</sup> digit with purulent drainage from first digit
- 

# Case

Laboratory findings and testing:

CBC: HGB:14.0, WBC 18.7 with 90% neutrophils

BMP: BUN 35, Cr. 1.7 K+ 4.7, glucose 350

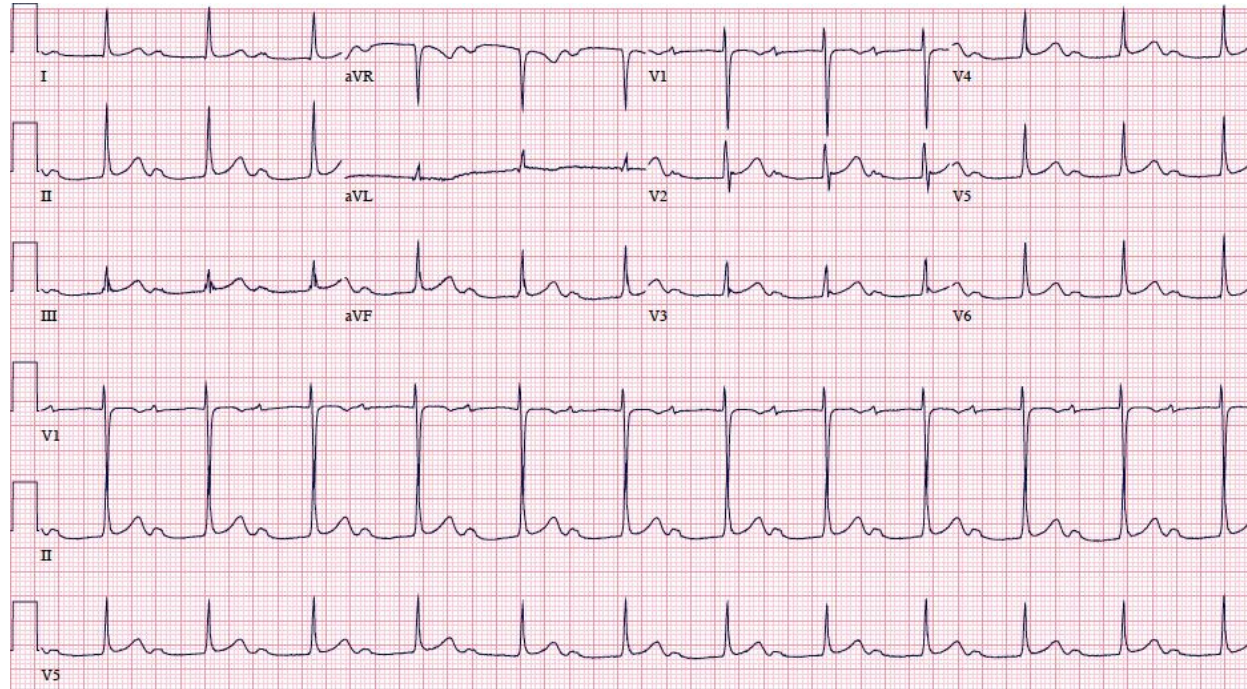
Troponin 0.057

3 sets of blood cultures pending

CXR: Pulmonary edema pattern




# Case 1




# Case 1

Based on clinical presentation and physical exam findings you suspect endocarditis. What predisposing cardiac disorder should you suspect?

1. Myxomatous mitral valve with mitral valve prolapse and regurgitation
  2. Dilated non-ischemic cardiomyopathy
  3. Bicuspid aortic valve
  4. Hypertrophic cardiomyopathy
  5. Patent foramen ovale
- 

# Comorbidities

- Valvular heart disease (rheumatic heart disease, mitral valve prolapse with regurgitation)
  - Congenital heart disease( ie, bicuspid aortic valve, VSD, patent ductus arteriosus, tetralogy of fallot)
  - Prosthetic heart valves (or other intracardiac devices)
  - Chronic Hemodialysis
  - HIV infection
- 

# Case 1


## **Bicuspid aortic valve**

- Murmurs are consistent with aortic stenosis and regurgitation
- Widened pulse pressure with significant aortic regurgitation
- History of murmur when he was younger
- Usually presents in 4<sup>th</sup> decade of life




# Case 1

Patient is given a 40mg dose of IV Lasix, which helps his dyspnea within 1 hour he has 1 liter of urine output. Vancomycin is started, admitted to a cardiac telemetry floor and a STAT echocardiogram is ordered. It reveals a bicuspid aortic valve, with valve area of 0.6 cm<sup>2</sup>, mean gradient of 50 mmHg, and moderate aortic regurgitation. There is mild dilation of the aortic root with a diameter of 4.2. Severe concentric LV hypertrophy is noted with an ejection fraction of 60%. Restrictive diastolic filling pattern is noted. There is a ill defined mobile mass noted on the ventricular aspect of the aortic valve. Artifact due to the heavy calcification of the valve makes visualization difficult.



# Case

Based on this information what is the best next test?

1. CT angiogram of the chest to evaluate for aortic dissection
  2. Cardiac catheterization to confirm no significant coronary artery disease so the patient can go to emergent surgery for valve replacement.
  3. Transesophageal echocardiogram
  4. Cardiac MRI
- 



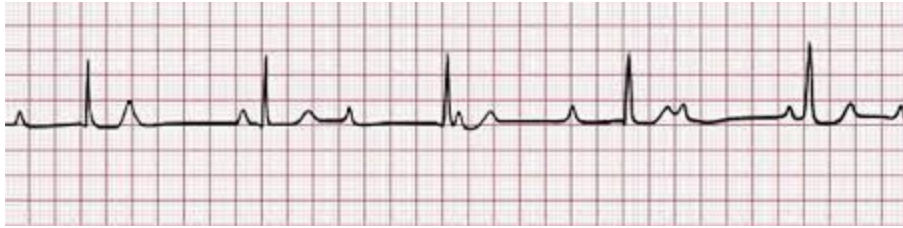# Case

It is 3AM in morning and 12 hours since patient initial presentation. You request a STAT TEE. An eager cardiology fellow who is more than happy to come in at this late hour rushes in. He preps the patient as a bleary eyed, tired attending walks into the patient room yawns and tells them to proceed.



# Case

TEE confirms diagnosis of Bicuspid valve. And a large 1.5cm vegetation is noted on the ventricular aspect of the non-coronary cusp, with obvious perforation of the leaflet. There is an large aortic root abscess noted. After the TEE is complete, the patient's telemetry changes.




# Case

The cardiology fellow places a temporary pacing wire for 3<sup>rd</sup> degree AV block while the cardiology attending (who is more awake now) calls the CT surgeon who is even more happy to be called in at 4AM



# Case

The lab calls stat results in during all of this. 3/3 blood cultures are positive for what organism?


1. Group B Streptococcus
  2. Haemophilus influenzae
  3. Methicillin resistant Staphylococcus aureus(MRSA)
  4. Candida Albicans
- 

# Case

The patient is rushed to surgery and undergoes aortic valve replacement with a bioprosthetic valve and replacement of the aortic root and ascending aorta. He eventually needs a permanent pacemaker during hospital stay as well, but after all of this does well. He is discharged home after 2 weeks, and now never misses an appointment with his cardiologist, and primary care physician.

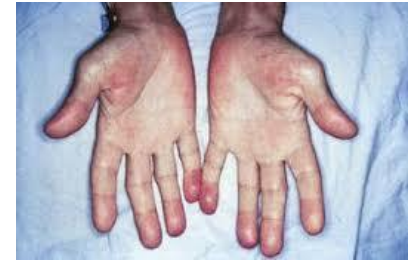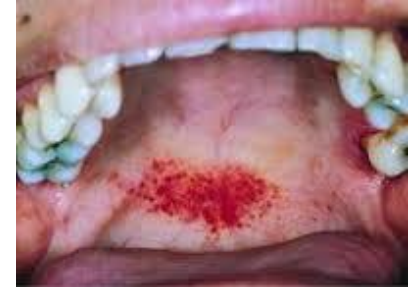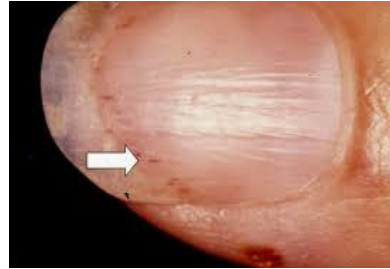


# Summary

- Endocarditis is becoming more common
    - Multiple reasons for this
    - Patient risk factors and behaviors
      - Age (people are living longer)
      - IV drug use-has been relatively stable nationwide but has increased in some areas
      - Structural heart disease
      - Other medical conditions
- 

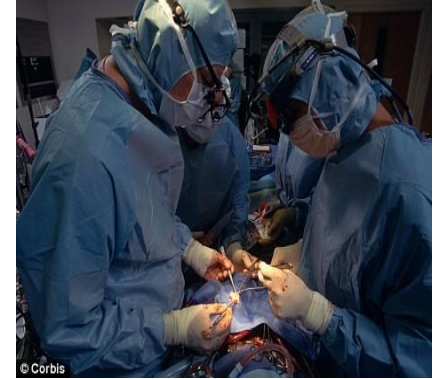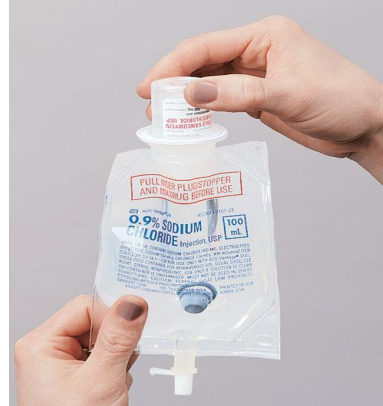# Summary

- Diagnosis
  - Clinical suspicion should guide workup
  - Remember fever present in 90% of patients
  - New onset murmur in 85% of patients
  - Cutaneous manifestations can be very helpful
  - Blood cultures essential to diagnosis and guide therapy, and monitor response
    - Markers of inflammation can also be helpful
  - 2D echo can be reasonable first test, but TEE would be needed to confirm or help exclude diagnosis



# Summary

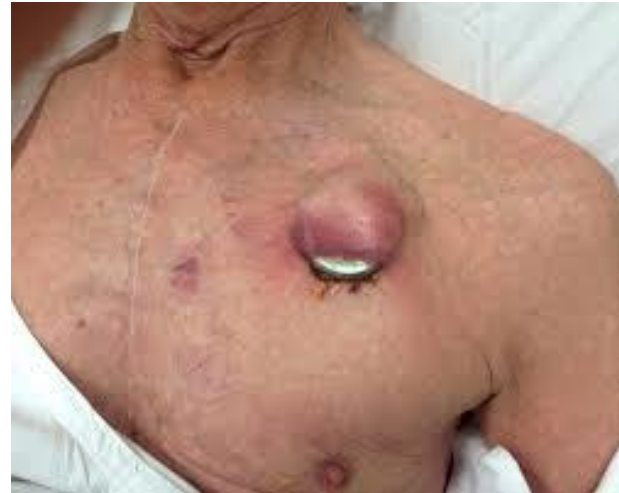- Treatment
- Depends on several factors
  - Organism
  - Site of infection (big difference between left and right sided endocarditis)
  - Size of vegetation
  - Complications
  - Etiology (ie drug users)
  - Patient comorbidities






# Summary

- Device Infections
  - Entire system needs to be removed
  - Antibiotic therapy
  - Reimplantation of systems after
  - Infection has been completely treated



# Summary

## Antibiotic prophylaxis in **high** risk patients only

- Prosthetic heart valves, including bioprosthetic and homograft valves
  - A prior history of IE
  - Unrepaired cyanotic congenital heart disease, including palliative shunts and conduits
  - Completely repaired congenital heart defects with prosthetic material or device during the first six months after the procedure (whether placed by surgery or by catheter intervention)
  - Repaired congenital heart disease with residual defects at the site or adjacent to the site of the prosthetic patch or prosthetic device
  - Valve regurgitation due to a structurally abnormal valve in a transplanted heart
- 

# Questions?

